

Marker LL, Dickman A. 2004. Dental Anomalies and incidence of palatal erosion in Namibian Cheetahs (*Acinonyx jubatus jubatus*). *J Mamm* 85(1):19-24.

Keywords: 1NA/*Acinonyx jubatus*/*Acinonyx jubatus jubatus*/anomaly/captivity/cheetah/dental anomaly/farmland/live-trap/morphology/palatal erosion/research/wild

Abstract: Two hundred and eight wild-caught cheetahs (*Acinonyx jubatus jubatus*) were live trapped on Namibian farmlands and examined for signs of dental anomalies. Three anomalies were recorded: erosion of the upper palate (possibly a predisposition to focal palatine erosion, where the first lower molar penetrates the palatine mucosa), crowding of lower incisors, and absence of one or both upper premolars. Just over 40% of cheetahs examined showed deep palatine erosion, and 15.3% of these had perforated upper palates. In addition, 31.7% of cheetahs examined had crowded lower incisors and 20.9% had one or both upper premolars missing. The incidence of focal palatine erosion is of particular interest as it has previously been recorded only in captive cheetahs, where it was attributed to a soft captive diet, and not previously recorded for wild individuals. To attempt further understanding of potential causes of such erosion, degree of erosion was examined in relation to sex, age, region, time in captivity, and occurrence of other dental anomalies. No relationship was found between severity of erosion and time spent in captivity, while juveniles showed more severe erosion than adult cheetahs. Cheetahs missing either one or both upper premolars showed a higher incidence of deep erosion, as was true for cheetahs that exhibited crowded lower incisors. The traditional explanation of focal palatine erosion being an artifact of captivity does not explain its occurrence in this sample population of cheetahs, the majority of which were raised entirely in the wild.

DENTAL ANOMALIES AND INCIDENCE OF PALATAL EROSION IN NAMIBIAN CHEETAHS (*ACINONYX JUBATUS JUBATUS*)

LAURIE L. MARKER* AND AMY J. DICKMAN

Cheetah Conservation Fund, P.O. Box 1755, Otjiwarongo, Namibia (LLM)

Wildlife Conservation Research Unit, Department of Zoology, South Parks Road, Oxford OX1 3PS, United Kingdom (AJD)

Two hundred and eight wild-caught cheetahs (*Acinonyx jubatus jubatus*) were live trapped on Namibian farmlands and examined for signs of dental anomalies. Three anomalies were recorded: erosion of the upper palate (possibly a predisposition to focal palatine erosion, where the first lower molar penetrates the palatine mucosa), crowding of lower incisors, and absence of one or both upper premolars. Just over 40% of cheetahs examined showed deep palatine erosion, and 15.3% of these had perforated upper palates. In addition, 31.7% of cheetahs examined had crowded lower incisors and 20.9% had one or both upper premolars missing. The incidence of focal palatine erosion is of particular interest as it has previously been recorded only in captive cheetahs, where it was attributed to a soft captive diet, and not previously recorded for wild individuals. To attempt further understanding of potential causes of such erosion, degree of erosion was examined in relation to sex, age, region, time in captivity, and occurrence of other dental anomalies. No relationship was found between severity of erosion and time spent in captivity, while juveniles showed more severe erosion than adult cheetahs. Cheetahs missing either one or both upper premolars showed a higher incidence of deep erosion, as was true for cheetahs that exhibited crowded lower incisors. The traditional explanation of focal palatine erosion being an artifact of captivity does not explain its occurrence in this sample population of cheetahs, the majority of which were raised entirely in the wild.

Key words: *Acinonyx jubatus*, cranial anomalies, congenital agenesis, dental, focal palatine erosion, Namibian cheetahs

Cheetahs (*Acinonyx jubatus*) are highly specialized, cursorial predators, with adaptations such as semiretractable claws, flexible spine, long legs and tail, and enlarged dew claws (Kitchener 1991; Taylor 2001). The species is recognized as having less genetic diversity than other felids (May 1995; Menotti-Raymond and O'Brien 1993; O'Brien et al. 1983, 1985, 1987), making the species potentially more vulnerable both to diseases and to ecological and environmental changes.

Only a century ago, cheetahs were widespread across Africa, Asia, and the Indian subcontinent, with the population numbering an estimated 100,000 individuals (Myers 1975). In the past hundred years, however, it has suffered a dramatic decline in both range and numbers, with a current estimate of fewer than 15,000 cheetahs left worldwide (Marker 1998). Cheetahs are now classified by the World Conservation Union as vulnerable or endangered

in the wild and are listed on Appendix 1 of the Convention on International Trade in Endangered Species (CITES 1984, 1992). Cheetah populations are restricted largely to sub-Saharan Africa, with remnant populations in North Africa and fewer than 100 Asiatic cheetahs (*A. j. venaticus*) left in Iran (Asadi 1998; Marker 1998; Nowell and Jackson 1996). Namibia, in southwest Africa, is home to what is estimated to be the largest remaining free-ranging population of cheetahs in the world and has historically been the source for most of the world's captive cheetahs (Marker 1998; Marker-Kraus 1997). The vast majority of wild cheetahs live in small, isolated populations outside protected game reserves, where they are often in conflict with humans due to livestock depredation, and most populations continue to decline (Marker 1998; Marker-Kraus and Kraus 1995; Nowell and Jackson 1996).

While cheetahs are declining in the wild, they do not fare particularly well in captivity either, where they have been hampered by abnormal spermatogenesis, low fecundity, and health problems (Evermann et al. 1988; Marker and O'Brien 1989; Marker-Kraus 1997; Marker-Kraus and Grisham 1993; Munson 1993; O'Brien et al. 1985; Wildt et al. 1993). One of

* Correspondent: cheetah@africa.com.na

the health problems identified was that of focal palatine erosion (FPE), a condition in which m1 perforates the upper palate, medial to M1 (Fitch and Fagan 1982; Phillips et al. 1993). In unaffected cheetahs, there is a slight indentation of the palatine mucosa in this area, to accommodate the cusp of the tip of m1.

The pathogenesis of FPE occurs where the lower molar's tip makes regular contact with the palatine mucosa, so the tooth eventually perforates the palatine bone, causing an associated inflammation of the palatine mucosal membrane with the potential for an extension into the nasal cavity. Oral defects observed in affected cheetahs range from sparse cellulitis, loss of pigmentation, and signs of inflammation, to large oronasal perforations extending through the palatine bone into the nasal passage (Fitch and Fagan 1982). Particles of food that lodge in the focal palatine perforations result in localized infection and further tissue damage. FPE has been reported in captive cheetahs as early as 10 months of age with a slight, localized cellulitis, although in young cats it may be overlooked as a typical teething disorder (Fitch and Fagan 1982).

This condition has never previously been reported in cheetahs that were born and raised in the wild, although the majority of reported cases have occurred in Namibian wild-caught animals living in captivity and captive-born animals from Namibian founders. When first reported, 86% of cheetahs with FPE came from one shipment from Namibia in 1970 or their descendants (Fitch and Fagan 1982). This oral defect was attributed to feeding cheetahs soft commercial diets lacking bones (Phillips et al. 1993) as well as to the possibility of specific family lines, renal disease, suppurative rhinitis, and it appears often, but not always, to accompany a maloccluded dentition (Fitch and Fagan 1982). This study aimed to investigate whether wild Namibian cheetahs also exhibited dental anomalies or whether FPE was an artifact of captivity.

The Cheetah Conservation Fund was established in Namibia in 1991, with the aim of learning more about the ecology of the cheetah on Namibian farmlands for conservation purposes. One aspect of the study involves the examination of cheetahs that are opportunistically captured by farmers, usually as a form of preventative management against cheetah predation on livestock and game animals. During such examinations, the opportunity was taken to investigate any dental anomalies that were observed in wild cheetahs. In addition to FPE, other dental anomalies observed in our sample population were crowding of the lower incisors and absence of one or both upper premolars. The crowding varies from slight crookedness to a severe condition where the incisors are arranged in 2 parallel rows. In domestic dogs and cats, such problems usually have a genetic basis, although nutritional status, juvenile viral infections, and metabolic disorders are also possible causes (Colmery and Frost 1986; Frost and Williams 1986). The absence of one or more premolars has been recorded in cheetahs before (Ewer 1973), but the objective in this study was to examine this phenomenon in relation to the other anomalies recorded, particularly erosion of the upper palate, in a wild population of cheetahs.

MATERIALS AND METHODS

Cheetahs were examined after being opportunistically live trapped on farms in Namibia (from 19°30'S to 23°30'S and from 16°E to 19°E) and had been held in captive situations for varying lengths of time before the Cheetah Conservation Fund was invited to examine them. These opportunistic captures usually occurred in response to farmers seeing signs of cheetahs on the farm and were often used as a form of preventative management in order to reduce cheetah depredation on livestock or game animals. All cheetahs examined were wild caught, and the region and date of capture were determined whenever possible. For this study, cheetahs that had been held in captivity for ≥ 30 days by the time of examination were considered to be captive animals, although none of the cheetahs had been raised in captivity, and the majority of cheetahs examined were later released back into the wild. The live traps used for capturing cheetahs measured 2×0.75 m, with trap release doors at each end and a trigger plate in the middle. Immobilization was achieved by using a hand syringe or blowpipe if the animal was still in a trap, while animals in a holding compound were darted using an air-pump dart gun or blowpipe (Telinject, Germany). In all immobilizing procedures, the anesthetic agent (Telazol: Tiletamine HCl and Zolazepam HCl, Fort Dodge Animal Health, Fort Dodge, Iowa) was administered intramuscularly in the hindquarters at a concentration of 100 mg/ml with a normal dose of 4 mg/kg. The animals showed signs of sedation, such as salivation, loss of motor control, and pupil dilation, within 4–6 min and were recumbent within 8–10 min.

Age classification was based both on previous studies and of experience with captive cheetahs and recaptured wild cheetahs of known age (Burney 1980; Caro 1994) and took into account mass, tooth wear and discoloration, gum recession, pelage condition, body measurements, social groupings of animals caught together, and reproductive condition (Marker and Dickman 2003). Additional information was gained by examining tooth eruption and other factors such as presence or absence of a nape mantle (longer, pale fur along the back of the neck and body that starts to diminish at 3 months of age). Physical condition was assessed, looking at factors such as coat condition, musculature, and ectoparasite load. This excluded injuries that were likely to have been sustained while in the capture cage, to give a better indication of condition in the wild.

To enable comparisons to be made, we followed the scheme set out in Phillips et al. (1993), which used 4 classes for analyses. The age estimation criteria used were juvenile cheetahs (24 months old or less at the time of exam) that had been captured before adult tooth eruption (before 7 months old), juvenile cheetahs captured at 7 months old or later, adult cheetahs (over 24 months old) that had been captured when juvenile (7–24 months old), and adult cheetahs that were captured when > 24 months old.

Each cheetah was examined for signs of FPE and scored on its severity. A score of 1 was assigned in cases where there was very little or no sign of erosion; a score of 2 indicated a medium erosion; and in cases where erosion had caused a deep depression, the condition was scored as 3. Some of the cases scored as 3 also showed actual FPE, signified by perforation of the mucosa, sometimes accompanied by bleeding, inflammation, and signs of foreign matter. Calipers were used to measure particular teeth, and interoral photographs were taken.

The overall score for analysis was developed as follows: 1, score of 1 on both sides of the palate; 2, score of 1 on one side and 2 on the other; 3, score of 2 on both sides; 4, score of 2 on one side and 3 on the other; and 5, score of 3 on both sides. None of the cheetahs examined had scores that did not fit this scheme (such as having a score of 1 on

TABLE 1.—Sample size of Namibian cheetahs examined for dental anomalies. All cheetahs were wild caught on farmlands in Namibia; cheetahs that had been held in captivity <30 days by the time of examination were categorized as wild, those held for ≥30 days were categorized as captive. Cheetahs were grouped using age at capture into the 4 age categories of Phillips et al. (1993).

	Juvenile, <7 months at capture	Juvenile, ≥7 months at capture	Adult, <24 months at capture	Adult, ≥24 months at capture	Unknown	Total
Wild						
Male	7	36	0	46	0	89
Female	4	21	2	23	1	51
Captive						
Male	9	2	0	23	7	41
Female	0	10	5	8	4	27
Total	20	69	7	100	12	208

one side and 3 on the other). The degree of erosion was considered to be severe if 1 or both sides of the palate were scored with a 3.

The number of upper premolars was recorded for each cheetah, with resulting scores of 0 (no premolar on either side), 1 (1 premolar present on 1 side), and 2 (both premolars present), and lower incisors were also examined to see whether there was any crowding.

Means significance testing was carried out using the parametric independent-samples *t*-test, preceded by Levene's test for equality of variances, and general linear model univariate analyses. Departures from expected ratios were analyzed using Pearson's chi-squared test. The nonparametric Spearman's rank correlation coefficient was used to determine the significance of relationships between variables measured on ordinal scales. All tests are 2 tailed unless otherwise stated.

RESULTS

We examined dental anomalies in 208 cheetahs between June 1992 and November 1999 (Table 1). Almost two-thirds (62.5%) of cheetahs examined were male, while a similar proportion (67.3%) were wild (i.e., had been held captive for <30 days). Precise dates of capture were available for 94.2% ($n = 196$) of the examined cheetahs and these animals could therefore be assigned to the 4 age classes described above. Overall, 89 juvenile cheetahs were examined, with 29.0% ($n = 20$) captured before the age of 7 months old (Table 1).

Although the single most common score assigned was 1, the incidence of deep erosion was relatively high, with 40.9% of the sample population classified as having a deep depression on at least one side of the palate (Table 2). Thirteen (15.3%) of these cheetahs (6.3% of the sample population) had perforated FPE (Table 3). Seven cheetahs that showed perforated FPE were completely wild and 6 had been in captivity for periods ranging from 2 months to 2 years.

Frequency of deep erosion among cheetahs that had been held captive for ≤ 30 days was 42.6% ($n = 29$), while the condition was slightly less frequent in wild cheetahs, with 40.0% ($n = 56$) showing severe erosion. There were no significant differences between wild and captive cheetahs, however, regarding overall score ($\chi^2 = 3.573$, $d.f. = 4$, $P = 0.467$), incidence of severe erosion ($\chi^2 = 0.133$, $d.f. = 1$, $P = 0.716$), or development of palatine perforation ($\chi^2 = 1.142$, $d.f. = 1$, $P = 0.285$). When only captive cheetahs were

examined, there was a slight positive correlation between score assigned and length of time spent in captivity, although it was not statistically significant ($r_s = 0.203$, $n = 57$, $P = 0.129$).

There was no difference between sexes in overall scores ($\chi^2 = 4.980$, $d.f. = 4$, $P = 0.289$), frequency of severe erosion ($\chi^2 = 2.017$, $d.f. = 1$, $P = 0.156$), or perforated FPE ($\chi^2 = 0.005$, $d.f. = 1$, $P = 0.941$). There was some slight variation, however, in scores between different regions of the country ($F = 2.026$, $d.f. = 8$, $P = 0.045$).

Juvenile cheetahs had significantly higher overall scores than adults ($\chi^2 = 13.645$, $d.f. = 4$, $P = 0.009$; Fig. 1), were subject to significantly more severe erosion ($\chi^2 = 9.930$, $d.f. = 1$, $P = 0.002$), and were significantly more likely to show perforated erosion ($\chi^2 = 5.971$, $d.f. = 1$, $P = 0.015$). There was no significant difference in the severity of the erosion seen between those juveniles captured before adult tooth eruption and those captured when older ($\chi^2 = 0.859$, $d.f. = 1$, $P = 0.354$). Adult cheetahs captured as juveniles had a lower incidence of severe erosion than those captured when adult, although the difference was not statistically significant ($\chi^2 = 3.725$, $d.f. = 1$, $P = 0.054$; Fig. 1).

The number of premolars that a cheetah had was significantly linked to severity of erosion—those cheetahs that had either one or both upper premolars missing showed a significantly higher frequency of severe erosion than those with both premolars present ($\chi^2 = 7.251$, $d.f. = 2$, $P = 0.027$). The frequency of severe erosion was also significantly higher among cheetahs that had crowded lower incisors than those that did not ($\chi^2 = 4.537$, $d.f. = 1$, $P = 0.033$), although there was no significant relationship for perforated FPE ($\chi^2 = 0.290$, $d.f. = 1$, $P = 0.590$).

There was a relationship between incidence of severe erosion in wild cheetahs and poorer physical condition (Fig. 2). Wild cheetahs with severe erosion were significantly less likely to be in excellent condition ($\chi^2 = 11.296$, $d.f. = 1$, $P = 0.001$). Wild cheetahs that had severe erosion were slightly lighter in body mass than those without a severe condition, with a mean mass of 33 kg compared with 36 kg (not statistically significant; $t = 1.203$, $d.f. = 135$, $P = 0.231$). There was no significant relationship between crowded incisors and either being in excellent physical condition ($\chi^2 = 0.673$, $d.f. = 1$, $P = 0.412$) or body mass ($t = 1.429$, $d.f. = 135$, $P = 0.155$).

TABLE 2.—Frequency of focal palatine erosion (FPE) scores (increasing in degree of severity from 1 to 5) assigned to wild and captive Namibian cheetahs of different ages. Cheetahs whose age was estimated at ≤ 24 months old at the time of examination were categorized as juvenile, those estimated at > 24 months old were categorized as adult.

	FPE 1	FPE 2	FPE 3	FPE 4	FPE 5	Total
Wild						
Juvenile	16	0	17	6	29	68
Adult	28	3	20	7	13	71
Unknown	0	0	0	1	0	1
Captive						
Juvenile	2	2	7	6	2	19
Adult	18	1	9	3	7	38
Unknown	0	0	0	3	8	11
Total	64 (30.8%)	6 (2.9%)	53 (25.5%)	26 (12.5%)	59 (28.4%)	208

DISCUSSION

Before investigation into the impact, prevalence, and etiology of dental anomalies can be undertaken, anomalies must be properly defined, characterized, and described in literature. The reporting of these conditions, particularly FPE, in entirely wild cheetahs, is important for other researchers to encourage further investigation and to aid in determining the ultimate causes of FPE and its impact on wild cheetahs.

Although FPE was first formally recorded in a captive cheetah population 20 years ago, it was believed not to occur in wild cheetahs captured as adults (Fitch and Fagan 1982; Phillips et al. 1993). During our long-term study conducted on Namibian farmlands, however, we not only found evidence of erosion in palates of wild cheetahs that may lead to FPE. We also found that FPE was not uncommon in wild cheetahs, and, even more notably, we discovered perforated palates (the most severe form of focal palatine erosion) in cheetahs that had never been held in captivity. This shows that preconditions for FPE exist in free-ranging cheetah populations throughout Namibia, with slight variations by region.

A common explanation for the development of FPE has been that cheetahs brought into a captive situation are fed soft diets (i.e., without the level of bone that would be present in a wild diet), which fail to sufficiently wear down the carnassials and hence lead to palatal damage (Fitch and Fagan 1982; Phillips et al. 1993). This does not explain, however, the results presented here, which show that cheetahs reared on an entirely natural, wild diet also suffer from the same problem. The effect of diet on tooth wear may indeed be important and is supported in this study by the evidence that degree of erosion appears to increase with time spent in captivity, although the trend here was not statistically significant. Captive cheetahs that we examined showed a slightly higher incidence of severe erosion, which suggests a captivity effect. However, we feel that focusing entirely on the issues of diet and captivity as the sole explanation may be misleading.

The juvenile cheetahs that we examined showed a significantly higher degree of erosion than did adults, regardless of

TABLE 3.—Frequency of other dental anomalies, apart from focal palatine erosion (FPE), observed in Namibian cheetahs examined. Anomalies included absence of one or more upper premolars, crowding of lower incisors, and perforation of upper palate as a result of severe FPE.

	Number of premolars			Crowded incisors		Perforated FPE	
	0	1	2	Yes	No	Yes	No
Wild							
Juvenile	5	3	60	17	51	5	63
Adult	10	4	57	25	46	2	69
Unknown	0	0	1	0	1	0	1
Captive							
Juvenile	1	2	16	6	13	5	14
Adult	6	7	25	10	28	1	37
Unknown	2	3	6	8	3	0	11
Total	24 (11.5%)	19 (9.1%)	165 (79.3%)	66 (31.7%)	142 (68.3%)	13 (6.3%)	195 (93.8%)

how old they were when captured. Juveniles were also more likely to suffer from perforated FPE. Although wild cheetahs consume primarily muscle and skin (Van Valkenburgh 1996), bone consumption at kills has been recorded to varying extents (Brain 1981; Phillips 1993). It seems likely that the gradual wear from gnawing on tough cartilage and bones will eventually blunt the teeth of adult cheetahs and reduce the extent to which the molar can irritate and penetrate the palatine surface.

Fitch and Fagan (1982) suggested that dental malocclusion could be a factor in the development of FPE, as FPE often accompanies a maloccluded dentition. If this is the case, it may be reasonable to hypothesize that cheetahs showing other dental anomalies, such as irregular placement of the lower incisors, would suffer from an increased frequency of erosion (FPE). Our results suggest that this is indeed the case, where cheetahs that had crowded incisors also exhibited more severe erosion, although crowding of the incisors did not seem to be linked to actual perforation of the palate. Similarly, more severe erosion was seen in cases where the study animal was missing either one or both upper premolars, indicating that although there may not be a causal relationship, there is some link between the incidences of these different traits.

Although less than one-third of cheetahs examined in this study showed crowding of incisors, this has either not been investigated or not been reported in other studies. It is possible that this is a local phenomenon due to environmental conditions specific to the Namibian cheetah population. An alternative explanation is that the defect is the result of both genetic and environmental factors and will be present in most or all cheetah populations throughout their range because of the extreme genetic homozygosity. Further research into free-ranging populations elsewhere in Africa is needed.

A high degree of genetic homozygosity is thought to have many effects on the phenotype of a given animal, and such homozygosity carries with it many consequences.

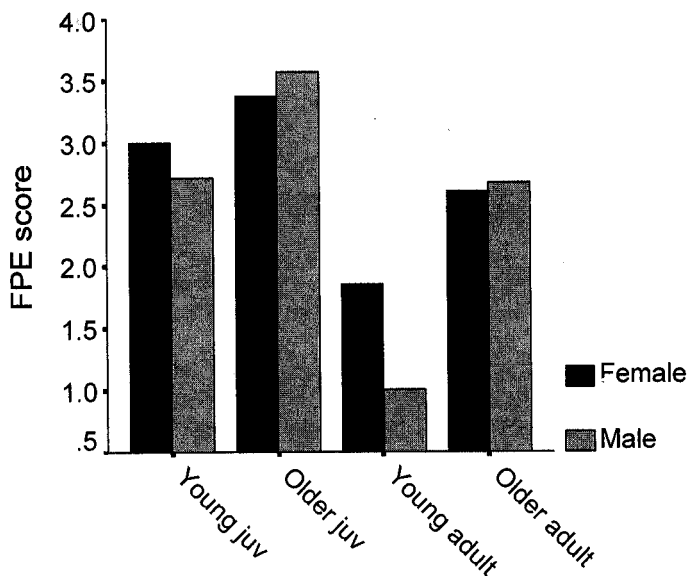


FIG. 1.—Mean scores for focal palatine erosion (FPE) for wild-caught cheetahs live trapped on farmlands in Namibia, separated by sex. Sample population of cheetahs was grouped by age into juveniles (aged ≤ 24 months at time of our examination), captured before the age of permanent tooth eruption (~ 7 months old; termed young juveniles below), juveniles captured when > 7 months old (older juveniles), adults (aged > 24 months at time of examination) captured as juveniles (young adults), and adults captured as adults (older adults), following Phillips et al. (1993).

Developmental and morphological defects have been reported in highly inbred animals: for instance, dental anomalies similar to those reported here have been observed in highly inbred populations of captive white tigers (Marker-Kraus 1997) while other morphological anomalies have been reported in Florida panthers, which also show very little genetic variability (Johnson et al. 2001; Roelke et al. 1993). The combined allozyme study on Namibian cheetahs and their morphological data suggests a genetic explanation (O'Brien et al. 1983; Wayne et al. 1986). The dental anomalies as described in this article may prove to be a genetic condition that predisposes an individual to developing advanced FPE. Extensive work has already been done on cheetah genetics (Menotti-Raymond and O'Brien 1993; O'Brien et al. 1983, 1985, 1987) and protocols exist for both DNA fingerprinting and microsatellite analysis (Gilbert et al. 1991; Menotti-Raymond and O'Brien 1993). Both of these techniques will be used in the near future to examine relatedness of animals with and without these morphological anomalies.

While the occurrence of FPE in wild cheetahs is interesting from a scientific standpoint, the most crucial factor is whether it appears to have a detrimental effect on cheetahs that exhibit it and on the population overall. Phillips et al. (1993) found with captive animals that even those cheetahs that had FPE were in excellent condition, but we found that, in our sample, there was a relationship between severe FPE and a loss of physical condition. It is not yet known what impact dental anomalies have on cheetah ecology nor what the long-term conse-

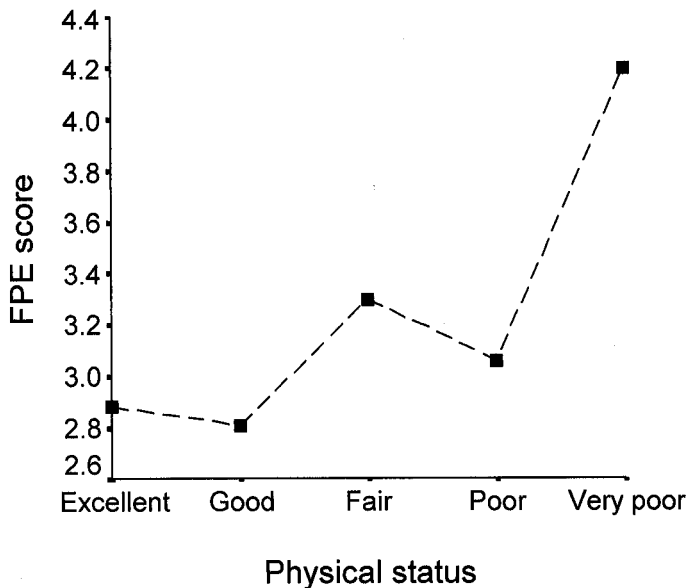


FIG. 2.—Relationship between mean scores of focal palatine erosion of wild-caught Namibian cheetahs and physical status determined using a 5-point scale from excellent to very poor. Physical status was determined by examining overall body condition. Symbols indicate mean for each group.

quences will be. Wild cheetahs are known to be victims of kleptoparasitism by larger, more powerful carnivores such as lions and hyenas (Caro 1994). If cheetahs with dental anomalies are slower at processing their kills, they may be further disadvantaged in the wild by losing a higher percentage of their prey in this way. In the wild, it is also unknown what the implications of physical defects, such as perforated palates as seen in extreme cases of FPE, may be for the overall health of affected individuals, although we know that they can lead to serious physical problems in captivity. Two examples can be cited: a captive cheetah reported with FPE died from severe kidney failure that was associated with oronasal osteomyelitis from FPE (Fitch and Fagan 1982), and kidney failure is one of the main causes of death for captive cheetahs (Marker-Kraus 1997; Munson 1993).

Overall, development of dental anomalies, including FPE, is likely to be complex and multifactorial, with genetics, diet, time spent in captivity, age, and skull morphology all playing a role. Reporting of these conditions in wild cheetahs is important for raising awareness among researchers in order to gain more information regarding prevalence and severity of such anomalies in different cheetah populations. This information will be crucial for a better understanding of how these conditions, particularly focal palatine erosion, may develop among wild cheetahs as well as those in captivity.

ACKNOWLEDGMENTS

The authors thank both the Namibian farmers and the Namibian Government, particularly the Ministry of Environment and Tourism, without whose support this long-term research would not have been possible. We are also grateful to the team of Cheetah Conservation Fund staff and volunteers, especially B. Schumann and C. Furillo,

for their assistance with the study, and to C. Clark, S. Clark, and 2 anonymous reviewers for their valuable input and critical discussions of earlier versions of this manuscript. Partial funding for this research was provided by the African Wildlife Foundation, the American Zoo Association Conservation Endowment Fund, the Angel Fund, the Bay Foundation, the Bush Entertainment Corporation, the Chase Foundation, Cheetah Conservation Fund-USA, Cincinnati Zoo, Columbus Zoo, Earthwatch Institute, Houston Zoo, Philadelphia Zoo, the Tapeats Foundation, Total South Africa, the Weeden Foundation, the WILD Foundation, White Oak Conservation Center, and the World Wildlife Fund South Africa Green Trust. Telazol for the project was donated by Fort Dodge Animal Health, Fort Dodge, Iowa. This research was reviewed and approved by the Cheetah Conservation Fund Scientific Advisory Board using guidelines approved by the North American Cheetah Species Survival Plan and permitted by the Namibian Ministry of Environment and Tourism.

LITERATURE CITED

- ASADI, H. 1998. The environmental limitations and future of the Asiatic cheetah in Iran. Report for the IUCN Cat Specialist Group, Gland, Switzerland.
- BRAIN, C. K. 1981. The hunters or the hunted? An introduction to African cave taphonomy. University of Chicago Press, Chicago, Illinois.
- BURNEY, D. A. 1980. The effects of human activities on cheetah (*Acinonyx jubatus*) in the Mara region of Kenya. M.Sc. thesis, University of Nairobi, Nairobi, Kenya.
- CARO, T. M. 1994. Cheetahs of the Serengeti Plains: group living in an asocial species. University of Chicago Press, Chicago, Illinois.
- CITES. 1984. Convention on International Trade in Endangered Species of Wild Flora and Fauna, Code Federal Register, Part 23.
- CITES. 1992. Quotas for trade in specimens of cheetah. Eighth meeting of the Convention of International Trade in Endangered Species of Wild Fauna and Flora. Document 8.22(rev.):1-5.
- COLMERY, B., AND P. FROST. 1986. Periodontal disease. *Veterinary Clinics of North America* 16:817-833.
- EVERMANN, J. F., J. HEENEY, M. ROELKE, AND S. J. O'BRIEN. 1988. Biological and pathological consequences of feline infectious peritonitis virus in captive cheetahs. *Archives of Virology* 102: 155-172.
- EWER, R. F. 1973. The carnivores. Cornell University Press, Ithaca, New York.
- FITCH, H. M., AND D. A. FAGAN. 1982. Focal palatine erosion associated with dental malocclusion in captive cheetahs. *Zoo Biology* 1:295-310.
- FROST, P., AND C. WILLIAMS. 1986. Feline dental disease. *Veterinary Clinics of North America* 16:851-873.
- GILBERT, D. A., C. PACKER, A. E. PUSEY, J. C. STEPHENS, AND S. J. O'BRIEN. 1991. Analytical DNA fingerprinting in lions: parentage, genetic diversity, and kinship. *Journal of Heredity* 82:378-386.
- JOHNSON, W. E., E. EIZIRIK, M. ROELKE-PARKER, AND S. J. O'BRIEN. 2001. Applications of genetic concepts and molecular methods to carnivore conservation. Pp. 335-358 in *Carnivore conservation* (J. L. Gittleman, S. M. Funk, D. W. Macdonald, and R. K. Wayne, eds.). Cambridge University Press, Cambridge, United Kingdom.
- KITCHENER, A. 1991. The natural history of the wild cats. Christopher Helm, A. & C. Black, London, United Kingdom.
- MARKER, L. 1998. Current status of the cheetah (*Acinonyx jubatus*). Pp. 1-17 in A symposium on cheetahs as game ranch animals (B. L. Penzhorn, ed.). Wildlife Group of the South African Veterinary Association, Onderstepoort, South Africa.
- MARKER, L. L., AND A. J. DICKMAN. 2003. Morphology, physical condition and growth of the cheetah. *Journal of Mammalogy* 84:840-850.
- MARKER, L. L., AND S. J. O'BRIEN. 1989. Captive breeding of cheetah in North American zoos (1871-1986). *Zoo Biology* 8:3-16.
- MARKER-KRAUS, L. 1997. Morphological abnormalities reported in Namibian cheetahs (*Acinonyx jubatus*). Pp. 9-18 in Proceedings of the 50th anniversary congress of VAN and 2nd African congress of the WVA.
- MARKER-KRAUS, L., AND J. GRISHAM. 1993. Captive breeding of cheetahs in North American zoos 1987-1991. *Zoo Biology* 12:5-18.
- MARKER-KRAUS, L., AND D. KRAUS. 1995. The Namibian free-ranging cheetah. *Environmental Conservation* 21:369-370.
- MAY, R. M. 1995. Population genetics. The cheetah controversy. *Nature* 374:309-310.
- MENOTTI-RAYMOND, M., AND S. J. O'BRIEN. 1993. Dating the genetic bottleneck of the African cheetah. *Proceedings of the National Academy of Sciences* 90:3172-3176.
- MUNSON, L. 1993. Diseases of captive cheetahs (*Acinonyx jubatus*): results of the Cheetah Research Council pathology survey, 1989-1992. *Zoo Biology* 12:105-124.
- MYERS, N. 1975. The cheetah, *Acinonyx jubatus*, in Africa. International Union for the Conservation of Nature and Natural Resources Monograph 4:9-90.
- NOWELL, K., AND P. JACKSON. 1996. Wild cats: status survey and conservation action plan. Burlington Press, Cambridge, United Kingdom.
- O'BRIEN, S. J., ET AL. 1985. Genetic basis for species vulnerability in the cheetah. *Science* 227:1428-1434.
- O'BRIEN, S. J., ET AL. 1987. East African cheetahs: evidence for two population bottlenecks? *Proceedings of the National Academy of Sciences* 84:508-511.
- O'BRIEN, S. J., D. E. WILDT, D. GOLDMAN, C. R. MERRILL, AND M. BUSH. 1983. The cheetah is depauperate in genetic variation. *Science* 221:459-462.
- PHILLIPS, J. A. 1993. Bone consumption by cheetahs at undisturbed kills: evidence of lack of focal palatine erosion. *Journal of Mammalogy* 74:487-492.
- PHILLIPS, J. A., M. B. WORLEY, D. MORSBACH, AND T. M. WILLIAMS. 1993. Relationship between diet, growth and occurrence of focal palatine erosion in wild-caught captive cheetahs. *Madoqua* 18: 79-83.
- ROELKE, M. E., J. S. MARTENSON, AND S. J. O'BRIEN. 1993. The consequences of demographic reduction and genetic depletion in the endangered Florida panther. *Current Biology* 3:340-350.
- TAYLOR, M. E. 2001. Locomotor adaptations by carnivores. Pp. 383-409 in *Carnivore behavior, ecology and evolution* (J. L. Gittleman, ed.). Cornell University Press, Ithaca, New York, 1:1-620.
- VAN VALKENBURGH, B. 1996. Feeding behavior in free-ranging, large African carnivores. *Journal of Mammalogy* 77:240-254.
- WAYNE, R. K., W. S. MODI, AND S. J. O'BRIEN. 1986. Morphological variability and asymmetry in the cheetah (*Acinonyx jubatus*). *Evolution* 40:78-85.
- WILDT, D. E., ET AL. 1993. Reproductive status of cheetahs in North American zoos: the benefits of physiological surveys for strategic planning. *Zoo Biology* 12:45-80.

Submitted 25 February 2002. Accepted 24 November 2002.

Associate Editor was William L. Gannon.