

Phillips JA, Worley MB, Morsbach D, Williams TM. 1991. Relationship among diet, growth and occurrence of focal palatine erosion in wild-caught captive cheetahs. *Madoqua* 18(2):79-83.

Keywords: 1NA/*Acinonyx jubatus*/captive experiments/cheetah/diet/disease/focal palatine erosion/FPE/research/teeth analysis/veterinary

Abstract: Forty-four wild-caught captive cheetahs of various ages were examined in Namibia for focal palatine erosion (FPE), a disorder characterized as penetration of the palatine mucosa by the lower first molar. Length of captivity varied from one month to more than four years. While captive these animals were fed a variety of diets ranging from meat scraps, to carcasses of rabbits and large domestic hoofstock. The occurrence of FPE was related to the type of diet fed, but only during the time period when the permanent teeth were erupting. Diet had no effect on producing RPE if individual cheetah were more than eight months old at the time of capture. There was no evidence that FPE occurred in wild cheetahs.

Relationship among diet, growth and occurrence of focal palatine erosion in wild-caught captive Cheetahs.

J.A. PHILLIPS, M.B. WORLEY, D. MORSBACH¹ AND T.M. WILLIAMS²

CRES, Zoological Society of San Diego, Box 551, San Diego, CA, 92112, USA

¹ Ministry of Wildlife, Conservation and Tourism, Private Bag 13306, Windhoek, Namibia

² Sea World Research Institute, San Diego, CA, USA

Received January 1991; accepted August 1991

ABSTRACT

Forty-four wild-caught captive cheetahs of various ages were examined in Namibia for focal palatine erosion (FPE), a disorder characterized as penetration of the palatine mucosa by the lower first molar. Length of captivity varied from one month to more than four years. While captive these animals were fed a variety of diets ranging from meat scraps, to carcasses of rabbits and large domestic hoofstock. The occurrence of FPE was related to the type of diet fed, but only during the time period when the permanent teeth were erupting. Diet had no effect on producing FPE if individual cheetah were more than eight months old at the time of capture. There was no evidence that FPE occurred in wild cheetahs.

INTRODUCTION

Populations of cheetahs *Acinonyx jubatus* have declined steadily due to habitat elimination, farming practices, and availability of food and water (Joubert & Mostert 1975; McVittie 1979). Although captive cheetahs have reproduced at a steady but albeit slow rate (when compared with other large felids in captivity), health problems have often plagued captive-born and-raised individuals (Caro *et al.* 1987; Everman *et al.* 1988). One such health problem, focal palatine erosion (FPE), has been identified in about 20% of the captive North American cheetah population (Fitch & Fagan 1982). FPE is characterized as penetration by the lower first molar (carnassial tooth) of the palatine mucosa medial to the upper first molar. Infection often develops as palate erosion progresses, and in severe cases, when the hard palate is penetrated, systemic disorders can also occur. This palate disorder has not been described in wild specimens found in museum collections, nor has the disorder been found in studies concerned with the health of free-ranging cheetahs (Caro *et al.* 1987). The study by Fitch and Fagan (1982) concluded that this condition was caused by malocclusion of the molars, possibly as a result of dietary factors. Analysis of diets fed to the affected cheetahs suggested that commercial 'soft' diets increased the incidence of FPE in captive situations. Although the study by Fitch and Fagan (1982) suggested a causal relationship between diet and FPE, their analysis was based solely on long-term captive animals, the majority of which were captive-born. The lack of comparative data from recently-caught juvenile animals that had been feeding on natural diets prior to captivity suggested that our understanding of FPE could be enhanced with further investi-

gation. Because the cheetah is threatened, and is currently being managed in breeding groups, the elimination of this problem is important. Additionally, should wild-caught animals supplement current captive populations, individual cheetah with FPE should not be exported.

The purpose of this study was to examine the relationships between diet, growth and FPE in wild-caught cheetah now kept on farms in Namibia. Particular attention was given to the timing of permanent tooth eruption and the relative rates of skull and skeletal development in juvenile cheetahs. In addition, influencing factors such as the duration of captivity, and the captive diet were correlated to the presence or absence of FPE.

MATERIAL AND METHODS

Animals: Forty-four cheetahs (21 M, 23 F) from central and northern Namibia were examined. Age of the animals ranged from three months to over seven years, whereas length of captivity ranged from one month to four years. Based on a visual estimate of body weight each animal was immobilized with a mixture of ketamine, 5 mg/kg (Ketaset, Bristol Laboratories, Syracuse, New York, 100 mg/ml), and xylazine, 0.3 mg/kg (Rompon, Haver-Lockhart, Fort Dodge, Iowa, 100 mg/ml). Immobilization drugs were administered with blow pipe darts. After collection of blood for separate studies, and determination of body weight and morphological measurements, the effect of the xylazine was reversed by the intravenous administration of yohimbine hydrochloride, 0.15 mg/kg (Yohimbine, Sirma Chemical, St. Louis, Missouri, 5 mg/ml).

Morphological measurements: Hind limb length, total body length, jaw width, maximum crown height of the lower first molars, and body weight were measured for each animal. Hindlimb length was the sum of the measurements for the femur, tibia and metatarsus, as located by palpation. Total body length was measured from the edge of the nares to the base of the tail. Jaw width was measured at the gum line between the lower canines and between the lower first molars (carnassial teeth). Maximum crown height of the lower first molar was measured from its contact edge with the mandible to the tip of the highest cusp with a digital caliper. Body weight was measured with a spring scale mounted on a tripod. All measurements were correlated with age as determined by presence of immature pelage (Morsbach, unpublished data) and the known life history of each cheetah. Three cheetah (12, 13, 33; Table 2) were examined at three months and eight months of age, all other cheetah were examined only once.

Individuals were examined for focal palatine erosion (FPE). Condition of the palate was assigned a numerical value as follows: 0, normal indentation (fossa) in the soft palate that accommodates the carnassial tooth; 1, ulcerated tissue present at the location of the fossa, but no penetration to the hard palate; 2, large ulcer with tissue deterioration exposing the hard palate; 3, deteriorated tissue and complete perforation of the hard palate. The palate and lower first molar of each cheetah were cleaned and macrophotographed with a reference scale. The contact area of occlusive wear on the lateral surface of the lower first molar was calculated using a modified version of a method for determining area ratios of body parts (Hildebrand 1952).

Life history: The life history of each animal, including the diet fed during the period of captivity were recorded. Diet and life history records of the specimens reported in Fitch and Fagan (1982) were re-examined. Special attention was given to the age at which individual animals were brought into captivity. **Skulls:** The skulls of 23 wild adult cheetahs were examined at the Ministry of Wildlife, Conservation and Tourism in Windhoek, Namibia and the Museum of Vertebrate Zoology, University of California at Berkeley, U.S.A. The skulls of six captive-raised adult cheetahs with FPE were also examined (Zoological Society of San Diego, U.S.A.). Crown height, occlusive wear pattern and jaw dimensions were measured as before. Skulls, jaws, and carnassial teeth of 16 African lions *Panthera leo*, 8 jaguars *P. onca* and 12 leopard *P. pardus* from the Ministry of Wildlife, Conservation and Tourism and Museum of Vertebrate Zoology were examined as reference species for comparative purposes. Particular attention was given to the amount of clearance between the carnassial tooth and accommodating fossa in the maxilla bone adjacent to the upper occluding molar.

Data Analysis: Adult cheetahs (age > 24 mo at the time of measurement) were divided into three groups: wild specimens (from museum collections) that had never been captive, captive individuals that had been introduced into captivity as adults (age > 24 mo at capture), and wild-

caught individuals that had been in captivity since they were juveniles with adult teeth (age 7 - 24 mo at capture). Juvenile cheetahs (age at the time of examination < 24 mo) were divided into two groups: individuals that were introduced to captivity before permanent tooth eruption (age < 7 mo) and individuals introduced into captivity after permanent tooth replacement (age > 7 mo).

Mean adult body dimensions (except crown height) were calculated for males and females separately. Body dimensions of individual juvenile or adult cheetah were then converted to percent of adult means. Percentile measurements were then grouped by age category and compared statistically (t-test). It was assumed that all linear body measurements of healthy individuals were asymptotic after 24 months of age. Crown height and percent occlusive wear of carnassial teeth were compared by ANOVA with LSD multirange test (adult groups) or t-test (juvenile groups).

RESULTS

Morphometric measurements: Data from juvenile cheetahs were insufficient to provide a comprehensive growth curve although percentile body dimensions of wild-caught, captive juvenile cheetahs were positively correlated with age through 12 months (Figure 1). Jaw width of juvenile cheetah less than 12 months old were substantially less (significant at 6, 7, and 8 months; $P < 0.05$, t-test) when compared to hindlimb length and total body length. At 12 months of age the percentile jaw dimension was not significantly different from percentile measurements for either hindlimb length or total body length, and all three body measurements for juveniles did not differ from mean adult measurements.

All juvenile animals measured at an age of seven or eight months ($n = 11$) had their permanent teeth. At that time the appendicular skeleton was approximately 77% of mean adult height, whereas the axial skeleton was 80% of adult length. The width of the lower jaw was 68% of the adult mean. Six month old cheetah ($n = 3$) did not show complete eruption of permanent teeth.

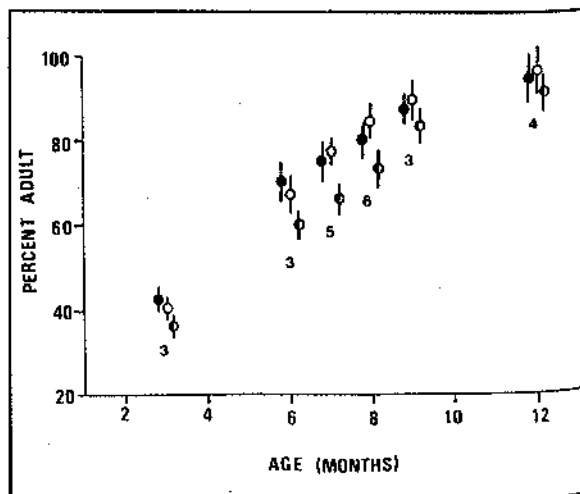


FIGURE 1. Total body length (v), hindlimb length (∇), and jaw width (○) of juvenile cheetahs expressed as percentage of mean adult measurement. Data are mean \pm (S.D.). Numbers indicate sample size.

TABLE 1. Crown height and percent occlusive wear of the lower first molar of adult and juvenile cheetah with permanent teeth. Data are mean \pm S.D. Sample size is in brackets.

	CROWN (mm)	OCCLUSIVE WEAR (%)
ADULTS		
museum specimens (23)	12.6 \pm 0.3	22 (3)
wild caught captive		
age > 24 mo at capture (14)	12.3 \pm 0.6	25 (4)
age < 24 mo at capture (8)	12.5 \pm 0.3	24 (4)
captive born w/FPE (6)	14.8 \pm 1.1 *	20 (6)
JUVENILES (with permanent teeth)		
captive before 7 mo old (14)	13.7 \pm 0.5 **	23 (6)
captive after 7 mo (5)	12.5 \pm 0.4	28 (4)

* $P < 0.001$, LSD = 0.23.

** $P < 0.05$.

Height of the lower first molar (carnassial tooth) of wild-caught adult cheetahs, wild-caught cheetahs older than seven months at capture, and museum specimens of wild cheetah were similar (Table 1); however, crown height of captive-raised adult cheetahs with focal palatine erosion (FPE) was significantly greater than those groups ($F = 21.57$, $df = 3,48$; $P < 0.001$). Crown height of wild-caught juveniles less than seven months of age at capture was statistically greater than juveniles brought into captivity after seven months of age (Table 1).

The area of wear on the lateral surface of the lower first molar was not different between animals with FPE and those without FPE (Table 1).

One exception was a juvenile (2, Table 2) that exhibited midfacial compression and had no contact point between the upper and lower first molars. In all other cases the area of contact with the medial surface of the upper molar was located centrally on the lateral surface of the carnassial tooth. Occurrence of FPE: Eight wild-caught juvenile cheetahs examined in Namibia had abnormal soft palates (Table 2). A single unifying characteristic of this group was that each animal had been introduced to captivity prior to the time of replacement of their primary teeth. Three juvenile cheetah that were introduced to captivity prior to primary tooth replacement did not exhibit FPE, and those three animals had the shortest carnassial teeth in the group of 11 (13.8 \pm 0.5 versus 12.6 \pm 0.4 mm). Cheetahs that had been introduced to captivity as older juveniles (age > 7 mo) or adults and had been maintained in captivity for periods of up to four years showed no signs of FPE ($n = 27$). Juveniles that had not yet shown eruption of the permanent teeth at the time of measurement were similarly unaffected; however, three juveniles that showed no sign of FPE prior to replacement of their primary teeth (12, 13, 33; Table 2) later developed FPE after primary tooth replacement. Thus, 11 of 14 juvenile

TABLE 2. Summary list of cheetah examined on private land in Namibia.

No.	Sex	AgeM	AgeC	Diet	Palate
01	M	3	2+	H/S	0
02	F	7m	3m	M	3
03	F	2+	1	D/M	0
04	M	2+	1	D/M	0
05	M	2+	1	D/M	0
06	F	5+	5+	D/M	0
07	M	7m	4m	D/M	2
08	M	7m	4m	D/M	2
09	M	7m	4m	D/M	2
10	F	5+	4	D/M	0
11	M	7m	4m	H/S	0
12	F	3m	1m	D/M	0*(3)
13	F	3m	1m	D/M	0*(3)
14	F	3+	2+	C	0
15	F	4	3+	C	0
16	M	3	2+	C	0
17	M	3+	2+	C	0
18	F	3+	2+	C	0
19	F	3+	2+	C	0
20	M	3	2+	C	0
21	F	3	2+	C	0
22	M	3	1+	C	0
23	M	3	1+	C	0
24	M	4	2+	C	0
25	M	3	1+	C	0
26	M	3	1+	C	0
27	F	1+	10m	C	0
28	F	9m	7m	C	0
29	F	12m	9m	D	0
30	F	12m	7m	D	0
31	F	5+	5+	D	0
32	M	6m	4m	M	2
33	M	3m	2m	M	0*(3)
34	M	5+	2+	M	0
35	F	7+	3	M	0
36	F	3m	1+	M	0
37	F	12m	8m	M	0
38	M	8m	3m	H/S	0
39	M	9m	3m	M/D	2
40	F	8m	4m	M	2
41	F	8m	4m	M	2
42	M	9m	6m	H/S	0
43	F	6m	4m	D	0
44	M	6m	4m	D	0

Legend: AgeM, age at date of measurement (years unless otherwise stated); AgeC, age at introduction to captivity; Diet, whole hare (H), sheep (S), meat scraps (M), cattle (C) or donkey (D); Plate, see methods. (*) Later developed EPE (measured at 8 month) with final palate index in brackets.

cheetahs that were exposed to captivity before they were seven months old developed FPE, whereas none of the juveniles introduced to captivity after replacement of their primary teeth ($n = 13$) developed FPE.

Diet appeared to have no measurable influence on the occurrence of FPE in cheetahs that were introduced to captivity as adults, or as juveniles with their secondary teeth; however, all eight juveniles with FPE and the three young juveniles that later developed FPE were all fed

meat scraps and disarticulated limbs from large hoofstock (donkey, cattle, horse).

With the exception of one animal (2, Table 2) all of these animals appeared to be in excellent health. The exceptional animal which had been fed only meat scraps since three months of age showed complete perforation of the hard palate and outward signs of rickets. The three juveniles that did not develop FPE were fed a diet of either whole hare or sheep carcasses (Table 2).

DISCUSSION

An earlier study (Fitch & Fagan 1982) suggested that focal palatine erosion (FPE) in the cheetah was a result of maloccluded teeth. Yet, because cheetahs have a complement of teeth that normally lack grinding surfaces (Smithers 1983), crowns of their carnassial teeth exhibit only modest wear on the lateral surface. In our study, museum specimens, wild-caught captive, and captive-raised cheetahs all had a similar area of wear on the medial surface of the lower first molar. There was little evidence that misalignment of the molars had occurred. If malocclusion in cheetahs was common one would expect that either the crowns would be overly worn because they were improperly in contact with one another, or the teeth would not be aligned laterally and no wear marks would be present. Neither appears to occur except in cases where midfacial growth patterns are abnormal due to metabolic or other problems (as in 2, Table 2).

The results of our study suggest that FPE in the cheetah is caused by several interactive conditions. First, the cheetah matures rapidly compared with other large felids, attaining 80 - 90% of its adult dimensions by an age of 8 - 10 months (Schaller 1968; Nowak & Paradiso 1983; Bertram 1975; Smuts et al. 1980). However, throughout their development, the jaw dimension of captive wild-caught juvenile cheetahs lags behind other body dimensions. Whether this trend occurs in wild juvenile cheetahs is unknown.

Similar growth patterns have been noted in large breed domestic dogs and previous studies with dogs provide clues as to why palatine problems may occur in cheetahs. Domestic dogs attain about 80% of their appendicular and axial skeletal growth by an age of eight months (Henrikson 1968), and exhibit a complete complement of permanent teeth at an age of about seven months (Arnall 1967a; Kremenak 1967). The domestic dog, like all other mammals studied, forms the crown of the permanent teeth prior to birth (Arnall 1967b). Post-weaning malnutrition has little effect on the post-eruptive size of the permanent teeth of dogs, but post-weaning malnutrition, especially on low calcium diets, can severely influence the rate of development of the appendicular and axial skeleton, but most notably the skull and jaw (Arnall 1967a). During the period of rapid skeletal growth juvenile dogs fed on low calcium diets exhibited poor jaw development but essentially normal sized teeth (Smith & Light 1945). The result was crowded, normal sized teeth in jaws that were abnormally small. This condition was

seen in cheetah 2 (Table 2), the extreme case which included midfacial compression along with severe FPE.

The lack of a natural diet appears to be a plausible cause of FPE in captive cheetahs. Wild cheetahs generally gnaw through the skin and rib cage of prey, feed on the brisket and internal parts in the abdominal cavity, and only rarely consume the limbs of prey (Morsbach, unpublished data). Thus, most of the postweaning calcium could be obtained from ribs and associated cartilage. Artificial diets low in calcium (e.g. meat scraps) could contribute to poor cranial and mandible development, and in the case of the cheetah this could result in penetration of the upper palate when normal-sized carnassial teeth were erupting into a smaller than average mouth. Because the clearance between the highest cusp of the carnassial teeth and the accommodating fossa in the palate is minimal in healthy cheetah, only a small decrease in skull growth would cause contact between the carnassial tooth and the soft palate. But, the possibility of occurrence of FPE in the large felids is not restricted to the cheetah.

Examination of the skulls and jaws of lion, leopard, and jaguar revealed clearance of less than 5 mm in all cases. The clearance would have been even less if the soft palate were present. Cheetahs may, however, be more prone to FPE because their development is temporally compressed when compared to the other large felids.

A second plausible cause of FPE in juvenile cheetahs is related to the rate of eruption of the permanent teeth. Tooth eruption, past normal crown height, generally occurs when there is less than normal resistance necessary to slow and eventually stop the eruption of teeth (Sessle 1965; Eccles 1965; Dienststein 1956). The dental pattern of all felids emphasizes cutting rather than grinding. Because the molars of cheetahs do not occlude centrally, the resistance forces that prevent abnormal crown height must be attributable to factors which lead to either greater tooth wear, and/or a reduction in the rate of eruption of permanent teeth during the rapid growth phase of juveniles. Captive cheetahs have often been fed meat scraps or commercially-prepared 'soft' diets which provide neither the abrasive nor resistant quality necessary to slow the rate of eruption or reduce crown height through abrasion. Crown height of captive adult cheetahs raised on soft diets from weaning ranged from 13.4 to 16.7 mm, fully averaging 2+ mm more than wild cheetahs with similar sized skulls and jaws. Such large carnassials can easily penetrate the soft tissue of the palate, especially early after the carnassials have erupted when the skull is substantially smaller than that of an adult. The typical feeding posture of the cheetah suggests that the shearing action of the carnassial teeth required to penetrate the hide and rib cage of prey could also produce the resistant forces required to slow the rate of eruption of the permanent teeth. Wild-caught adult cheetahs and museum specimens showed a maximum crown height of 13.3 mm.

Our examination of wild-caught cheetahs suggests that only those animals introduced to incomplete diets before

erupted of their permanent teeth will develop FPE. Re-examination of three cases reported by Fitch and Fagan (1982) supports this conclusion. Of the 15 cheetahs with FPE in that study, three exhibited minimal palate problems (animals 9, 14, and 15 in their Table 2). Those three animals were 14 or more years old at death and were reported after 24 months of age. Even though these animals were subsequently fed an incomplete commercial diet they had already passed the critical period and would not have been expected to develop FPE. That these three cheetahs exhibited only minor palate problems (between 0 and 1 on our scale) may have been an age-related deterioration.

The size-weight base of prey items for cheetahs is narrow (Schaller 1968). Among possible explanations for this limitation are the cheetah's inability to secure larger prey without risk of injury (McVittie 1979). Whereas field observations support this suggestion (Schaller 1968) other data suggests that the post-kill feeding behavior of the cheetah could also limit the prey base due to anatomical constraints. Because cheetahs often leave the limbs of prey intact, the size and strength of the cheetah's jaw may not be sufficient to rapidly consume these body parts. Additionally, the maximum gap between the shearing teeth may be insufficient to consume axial portion of prey species at the upper size limit of the prey base. Thus, merely supplementing the diet of captive cheetahs with "chewing" bones may be ineffective in mitigating the problem of FPE if the bones are too large to be manipulated by the cheetah. As a result, the ideal diet in captivity would provide smaller prey items conducive to the anatomy of the jaw. This would provide proper wear and adaptive resistance to the molars responsible for causing FPE.

ACKNOWLEDGEMENTS

This research was supported by a grant from the Conservation Consortium and was conducted while JAP and MBW were on annual leave. We thank the Ministry of Wildlife, Conservation and Tourism, Namibia, for approving this project, and the farmers of Namibia for their cooperation.

REFERENCES

- ARNALL, L. 1967a. Some aspects of dental development in the dog - I. Calcification of crown and root of the deciduous dentitions. *J. Small Anim. Pract.* 1: 69-177.
- ARNALL, L. 1967b. Some aspects of dental development in the dog - II. Eruption and extrusion. *J. Small Anim Pract.* 1: 259-267.
- BERTRAM, B.C.R. 1975. Weights and measures of lions. *E. Afr. Wildl. J.* 13: 141-143.
- CARO, T.M., HOLT, M.E., FITZGIBBON, C.D., BUSH, M., HAWKEY, C.M. & KOCK, R.A. 1987. Health of adult free-living cheetahs. *J. Zool., London* 212: 573-584.
- DIENSTEIN, B. 1956. Tooth development and eruption. *J. Dental Res.* 35: 479-490.
- EVERMAN, J.F., HEENEY, J.L., ROELKE, M.E., MCKEIRMAN, A.J. & O'BRIEN, S.J. 1988. Biological and pathological consequences of feline infectious peritonitis virus infection in the cheetah. *Archives of Virology*; 102: 155-171.
- FITCH, H.M. & FAGAN, D.A. 1982. Focal palatine erosion associated with dental malocclusion in captive cheetahs. *Zoo Biology* 1: 295-310.
- HENRIKSON, P. 1968. Periodontal disease and calcium deficiency: An experimental study in the dog. *Acta Odontologica Scandinavica* 26: Suppl. 50, 9-106.
- HILDEBRAND, M. 1952. An analysis of body proportions in the Canidae. *Amer. J. Anat.* 90: 217-256.
- JOUBERT, E. & MOSTERT, P.K.N. 1975. Distribution patterns and status of some mammals in South West Africa. *Madoqua* 9: 6-44.
- KREMENAK, C.R. 1967. Dental exfoliation and eruption chronology in beagles. *J. Dent. Res.* 46: 686-693.
- MCVITTIE, R. 1979. Changes in the social behavior of South West African cheetah. *Madoqua* 11: 171-184.
- NOWAK, R.M. & PARADISO, J.L. 1983. Walker's mammals of the world, 4th edition. Baltimore: Johns Hopkins University Press.
- SCHALLER, G. 1968. Hunting behavior of the cheetah in Serengeti National Park. *E. Afr. Wildl. J.* 6: 95-100.
- SESSLE, B. 1965. Impeded and unimpeded eruption in the rat incisor. *J. Dent. Res.* 44: 1198.
- SMITH, C.A.H. & LIGHT, R.F. 1945. Low calcium diets: Dental effects. *J. Dent. Res.* 24: 53-55.
- SMITHERS, R.H.N. 1983. The mammals of the Southern African subregion. Pretoria: University of Pretoria Press.
- SMUTS, G.L., ROBINSON, G.A. & WHYTE, I.J. 1980. Comparative growth of wild male and female lions (*Panthera leo*). *J. Zool., London* 190: 365-373.